

Segmentation and Analysis of Breast Tumors on Ultrasonography

Miguel Alemán-Flores¹, Patricia Alemán-Flores², Luis Álvarez-León¹,
M. Belén Esteban-Sánchez¹, Rafael Fuentes-Pavón²
and José M. Santana-Montesdeoca²

¹Departamento de Informática y Sistemas,
Universidad de Las Palmas de Gran Canaria, 35017, Las Palmas, Spain
²Sección de Ecografía, Servicio de Radiodiagnóstico,
Hospital Universitario Insular de Gran Canaria, 35016, Las Palmas, Spain
Email: maleman@dis.ulpgc.es

Abstract. Ultrasonography provides some criteria which help the physicians decide whether a certain solid tumor is benign or malignant. However, it is one of the most difficult types of images to assess. The automatic segmentation and analysis of ultrasonography can help the physicians by providing some techniques and measures to classify the tumors. In this paper, we present a new approach in the segmentation of ultrasound images of breast nodules, based on active contours technique. Moreover, we present a common framework for the extraction of a set of robust, reproducible and precise parameters, by means of computer vision techniques, such as ellipse location, corner extraction or gradient estimation.

1 Introduction

The analysis of ultrasound images of breast nodules can help the specialists diagnose malignant tumors and avoid unnecessary biopsies. This paper presents a new approach to the computer-aided segmentation and analysis of the nodules. Some previous works try to adjust the parameters of the ultrasound systems to help in the decision making process [1], segment the tissues [2], or deal with certain particular aspects of the nodules, such as texture [3] or general shape [4].

The semi-automatic method we propose consists of a combination of the classical active contours technique, adapted to the special characteristics of the ultrasound images, and a region growing algorithm used to extract the initial snake, in order to avoid its manual delineation. Once the nodule has been segmented, we analyze a series of criteria regarding the benignity/malignancy of the tumor. These include hyperechogenicity, ellipsoid shape, two or three gentle lobulations and thin echogenic capsule as benignity criteria. On the other hand, hypoechogenicity, acoustic shadowing, taller-than-wide shape, ramifications, microlobulations, angular margins, spiculation and calcifications have been described as malignancy criteria [5].

The rest of the paper is organized as follows: First, in Sect. 2, we describe the proposed method for nodule segmentation. In Sect. 3, we show a common framework for the analysis of the different diagnostic criteria. Finally, we give an account of our main conclusions.

2 Nodule Segmentation

Ultrasound images are corrupted by speckle, which makes their examination difficult and limits the application of automatic computer analyses. Snakes allow obtaining the contour of the objects with a high accuracy. Their main disadvantage is the need for an initial approximation, which, in our case, would require the selection a set of 20 to 30 points to delimit the contour or the nodule. To avoid this time-consuming task, we use the truncated median filter to reduce speckle noise and a region growing algorithm based on the magnitude of the gradient, which is extracted in the filtered image by means of the structure tensor. A threshold is set and a point is selected as seed by the specialist.

In [6], the authors proposed an active contours technique based on the partial differential equation:

$$\frac{\partial u(x, y)}{\partial t} = g(I(x, y)) |\nabla u(x, y)| \operatorname{div}\left(\frac{\nabla u(x, y)}{|\nabla u(x, y)|}\right) + \lambda \nabla g(I(x, y)) \nabla u(x, y) \quad (1)$$

where $u(x, y; 0) = u_0(x, y)$ is the initial snake contour, $\lambda \geq 0$ is a constant that guides the internal force of the snake and $g(I(x, y))$ represents the stop function, the external force that attracts the snake $u(x, y)$ to the real contour of the object. It is an edge detector that must be selected according to the characteristics of the image. A typical choice of $g(I(x, y))$ is:

$$g(I(x, y)) = \frac{1}{\sqrt{1 + \alpha |\nabla I_s(x, y)|^2}} \quad (2)$$

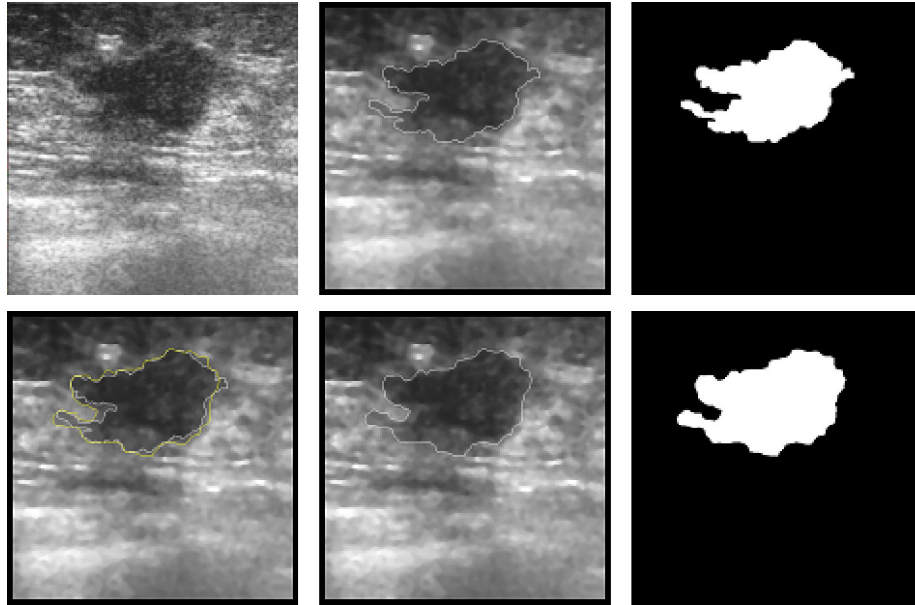
where $\alpha \geq 0$ is a constant and $I_s(x, y)$ denotes the smoothed version of the original image. We use a multiscale implementation of (1) that allows adapting the external and internal forces within each scale. Figure 1 shows an example of initial and final segmentations.

3 Feature Extraction

In this section, we will describe the criteria that will be considered in the diagnosis of the nodules, both benign and malignant.

The hyper or hypoechogenicity of a nodule is measured with respect to the echogenicity of the fat of that particular woman. A nodule produces acoustic shadowing if the ultrasound is attenuated when crossing through it. These two features are processed by simply considering the mean intensity of the areas

Fig. 1. Example of active contour segmentation of a solid breast nodule. From top to bottom and from left to right: original image, initial snake, initial segmentation, comparison of initial and final snakes, final snake and final segmentation

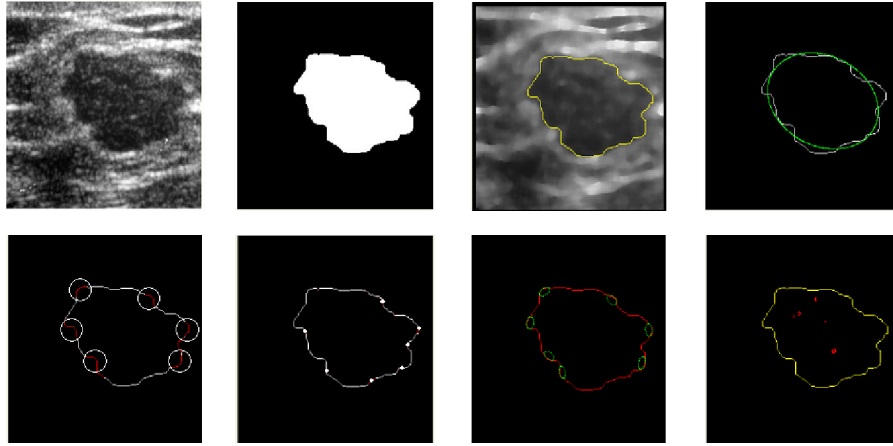


involved in the criteria, i.e. the segmentation, the region under it and a fat region selected by the specialist.

A nodule is said to be taller than wide when it is greater in the direction normal to the skin than in the parallel ones. On the binary segmented image, we calculate the mean width and the mean height of the nodule and the ratio of both measures indicates its disposition. Furthermore, those points whose vertical distance to the center is larger than the mean width indicate the areas where the nodule is growing vertically.

An ellipsoid shape increases the probability of benignity, and even if a nodule is not elliptical, it is considered as benign if it presents two or three smooth, well circumscribed and gentle lobulations. The usual techniques to locate ellipses in an image are based on the Hough transform or the principal axis estimation [7, 8]. We propose an algorithm to estimate, in a very accurate way, the ellipse location by minimizing the mean distance from a set of points to the ellipse. This minimization criterion has a more physical meaning and provides a very accurate estimation. The distance is divided by the square root of the area of the nodule to normalize it. If the nodule has not an ellipsoid shape, we must determine if it has two or three gentle lobulations. We proceed as in the previous case, but instead of searching for an ellipsoid which fits the whole contour, we search for large lobulations which fit a large region of the contour each, which together cover

Fig. 2. Example of the extraction of the diagnostic criteria. From top to bottom and from left to right: original image, nodule segmentation, contour of the nodule, ellipse extraction, angular margins, spiculation, microlobulations and calcifications



the whole contour, whose axes do not differ strongly in their lengths, and whose centers are clearly separated. For the extraction of the ramifications, we locate those points whose distance to the ellipse which best fits the contour is large. In order to prevent the ramifications from influencing the position and dimensions of the main ellipse, an iterative scheme has been used in which the points which are very far from the ellipse are eliminated and the ellipse is recalculated. After a few iterations, the ellipse which is extracted is much more representative of the central region and the ramifications are more clearly identified.

Those small areas inside the nodule where the intensity and the magnitude of the gradient is quite high have been selected as calcifications. To locate the areas where spiculation appears, we extract the orientation of a window around every contour point. In this case, not only the magnitude of the gradient, but also its orientation is significant. When the orientation in a region around a contour point is quite dissimilar to that of such point, it is considered as a spiculation zone. The capsule of the nodule is extracted by eroding the selected region and analyzing the eroded points. The echogenicity of the capsule is measured, as the previous ones, from the mean intensity of the region.

We can locate angular margins by searching for pseudo-straight lines on the contour of the nodule. In order to select those angles which are significant for the study, the lines must fit the contour, they must be long enough and the difference in the orientation must be less than $\pi/2$. Microlobulations are observed as small ellipsoid arcs in certain regions of the contour and are frequently associated with angular margins. For this feature, a similar technique as the one used when extracting the general ellipse is applied. However, in this case, we search for segments of the contour which can be approximated by a part of an ellipse and whose size and axes are small.

Not only these techniques allow locating the regions of interest for each diagnostic criteria, but they also provide quantitative measures of their relevance, in order to improve the diagnosis. Figure 2 illustrates the analysis of different diagnostic criteria.

4 Conclusion

We have presented a new approach for the segmentation and analysis of solid breast nodules on ultrasound images. The importance of an accurate delineation of the contour in order to analyze a series of diagnostic criteria makes it very relevant to develop a precise technique to filter and segment the images. By means of a denoising filter, a region growing technique, and an adaptive multi-scale snake implementation, we have obtained quite satisfactory results in the extraction of the contour of the nodules.

The precision of the contour, the possibility of extracting numerical measures and the location of the regions of interest make the diagnosis easier and more reliable. The combination of the different criteria to provide more representative measurements and the adjustment of the parameters will increase the sensibility and specificity of the discrimination. The results provide support to the application of computer vision techniques, not to substitute the appreciation of the physicians, but to improve the classification of the tumors through robust, reproducible and accurate techniques.

References

1. Kuo WJ, Chang RF, Moon WK, et al. Computer-Aided Diagnosis of Breast Tumors with Different US Systems. *Acad Radiol* 2002;9(1):793–799.
2. Kauffhold J, Chan R, Karl WC, Castanon DA. Ultrasound Tissue Analysis and Characterization. In: *Procs. of SPIE*; 1999. p. 73–83.
3. Chen DR, Chang RF, Juang YL. Computer-Aided Diagnosis Applied to US of Solid Breast Nodules by Using Neural Networks. *Radiology* 1999;213(1):407–412.
4. Cheng CM, Chou YH, Han KC, et al. Breast Lesions on Sonograms: Computer-Aided Diagnosis with Nearly Setting-Independent Features and Artificial Neural Networks. *Radiology* 2003;226(1):504–514.
5. Stavros AT, Thickman D, Rapp CL, et al. Solid Breast Nodules: Use of Sonography to Distinguish between Benign and Malignant Lesions. *Radiology* 1995;196(1):123–134.
6. Caselles V, Kimmel R, Sapiro G. Geodesic Active Contours. *International Journal of Computer Vision* 1997;22(1):61–79.
7. Ahn SJ, Rauh W, Warnecke HJ. Least-Squares Orthogonal Distances Fitting of Circle, Sphere, Ellipse, Hyperbola, and Parabola. *Pattern Recognition* 2001;34(1):2283–2303.
8. Halif R, Flusser J. Numerically Stable Direct Least Squares Fitting of Ellipses. In: *Procs. of WSCG 98*; 1998. p. 125–132.